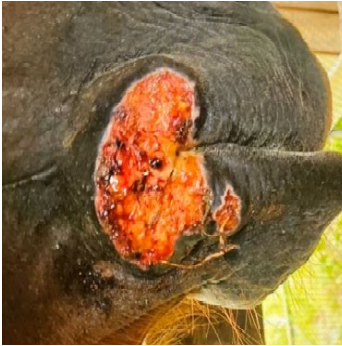

## CASE STUDY

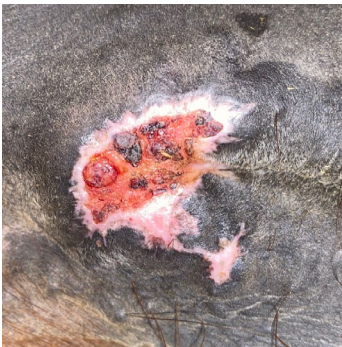# Summer Sore



**Case presentation: On June 17, 2022,**

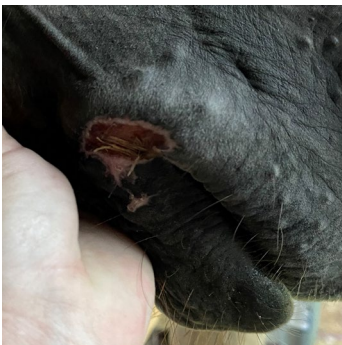
a 19-year-old Red Horse presented to Topgun Veterinarian Service, Rock Hill, SC, with a large Summer Sore on the commissure of the right side of the mouth. The horse was treated orally with Ivermectin and topically with Ivermectin and Silver Sulfadiazine Dexamethasone weekly for one month. The Summer Sore persisted and showed no sign of improvement.

**On July 19, 2022,** 1.5 cc of RenoVō® allograft was implanted at the discretion of the veterinarian and distributed subcutaneously around the Summer Sore edges.



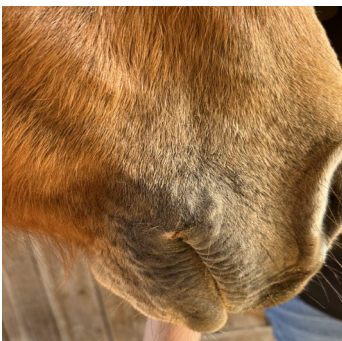**On July 31, 2022,**

twelve days following the RenoVō® implantation, the Summer Sore was re-epithelizing and had significantly decreased in size.



**On August 6, 2022,**

eighteen days following the RenoVō® implantation, the Summer Sore was almost completely healed.



**On April 3, 2023,**

the Summer Sore was completely resolved with no evidence of re-emergence to date.

**RenoVoEquine.com**

(501) 708-5000 | [info@RenoVoEquine.com](mailto:info@RenoVoEquine.com)

308 E FM 1830, Building 2, Suite A, Argyle, TX 76226

RenoVō® is a registered trademark of Equine Amnio Solutions, LLC | SOP-MKT-025 Rev 2

**RENOVō**<sup>®</sup>  
equine allograft