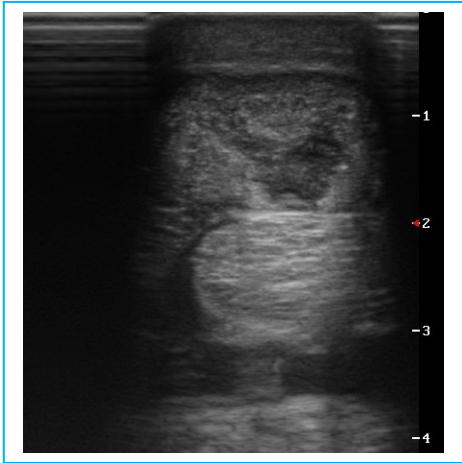


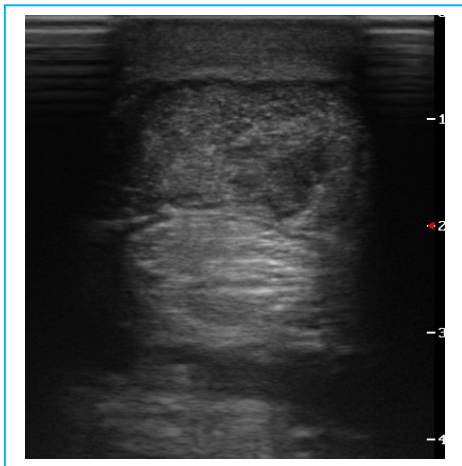

RenoVō® CASE STUDY: SUPERFICIAL DIGITAL FLEXOR TENDON (RH)

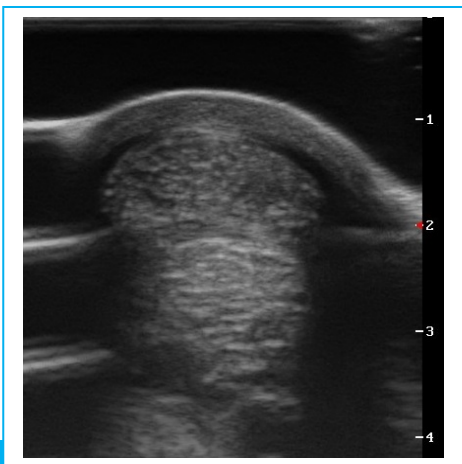
Horse Name: Hands Free



Case presentation: On June 9, 2016, a 9 year old Warmblood jumping horse presented with a superficial digital flexor tendon injury of the right hind leg. The horse was treated with stem cell injections. After 10 months of rest and rehabilitation, the horse slowly went back to jumping but in late August 2018, the horse re-injured the SDFT. The horse underwent shockwave treatments and experienced marginal improvement. On January 18, 2019, after more than 2 years following the initial injury and a multitude of treatments, a 1.5 cc of RenoVō® was implanted at the discretion of the veterinarian into the lesion under ultrasound guidance.



On February 27, 2019, only 1 Month after the RenoVō® implantation, the attending veterinarian observed a significant improvement under ultrasound. At the recommendation of the veterinarian, the horse continued resting.



On April 22, 2019, 3 Months following the RenoVō® implantation, the lesion was finally resolved, and horse was sound. **“In October 2019, Hands Free went back to jumping and competed at 1.15m and jumped clean the entire week and had no change in his soundness,”** says the owner. The horse is still sound to date and is now showing at 1.25m.

308 E FM 1830, Building 2, Suite A, Argyle TX 76226
501-708-5000

RenoVō® is a registered trademark of Equine Amnio Solutions, LLC

SOP-MKT-012 rev 4